

## Sample SPEX Questions

GENERAL INSTRUCTIONS: Read each question carefully and in the order in which it is presented. Then select the one best response option of the choices offered. There may be 4 to 6 response options. More than one option may be partially correct. You must select the **ONE BEST** answer and fill in the corresponding blank line on the answer sheet. The answer sheet and answer key are provided at the end of Block 2.

Some items are grouped together around a clinical vignette as a set or case; be particularly careful to read and answer these cases or sets of items in the order they are presented.

The items in this exam are divided into 2 blocks:

Block 1	Items 1–43
Block 2	Items 44–86

### Block 1

Items 1–43; Time - 57 minutes

**ALL ITEMS REQUIRE SELECTION OF ONE BEST CHOICE.**

- A 14-year-old girl, who has received three courses of chemotherapy for Hodgkin disease, is brought to the office by her father because of worsening cough, shortness of breath, a low-grade fever and fatigue for the past 2 days. No one at home is ill. She says she is taking no medications. Her vaccinations are up-to-date. She attends a private school. Vital signs are temperature 37.1°C (98.8°F), pulse 100/min, respirations 35/min, and blood pressure 110/72 mm Hg. Oxygen saturation on pulse oximetry is 87% while breathing room air. Physical examination discloses a few coarse breath sounds in the lower lobes and retractions. Chest x-ray shows no masses and a mild interstitial pattern. No infiltrates or effusions are noted and heart size is normal. Which of the following is the most appropriate step at this time?

  - Admit the girl to the hospital for high-dose trimethoprim-sulfamethoxazole therapy
  - Begin isoniazid therapy in the girl and test the family for tuberculosis
  - Prescribe ciprofloxacin and schedule a return visit for tomorrow
  - Prescribe oral fluconazole for the girl
  - Schedule a lung biopsy
- A 14-year-old African American girl comes to the office for the first time for a sports physical examination. She is asymptomatic. Her medical history is unremarkable. Family history shows that her maternal grandmother had a myocardial infarction at age 65 years. Her mother has hypertension that is well controlled with antihypertensive medication. Vital signs are temperature 37.2°C (99.0°F), pulse 86/min, respirations 16/min, and blood pressure 112/74 mm Hg. Height is 165 cm (5 ft 5 in; 75th percentile) and weight is 45 kg (99 lb; 25th percentile). Physical examination shows a grade 2–3/6 systolic heart murmur at the left sternal border. The second heart sound (S<sub>2</sub>) is loud with fixed splitting and is heard best in the second left intercostal space. The family is anxious and requests an answer regarding the patient's sports participation. Which of the following is the most appropriate advice to give the patient and her parents?

  - Allow her to participate in all sports
  - Allow her to participate in noncontact sports only
  - Allow her to participate in sports but recommend cardiac catheterization
  - Allow her to participate in sports but recommend echocardiography
  - Prescribe prophylactic antibiotics for use prior to each game

Items 3–4

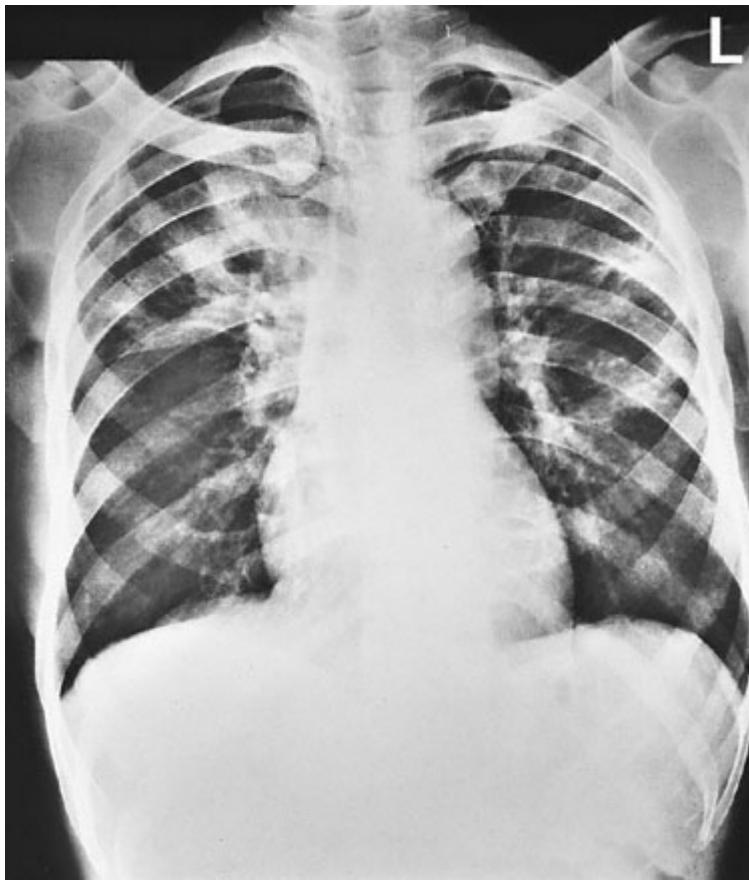An 81-year-old woman is being prepared for discharge following a 3-week stay in the hospital for repair of a fractured hip that she sustained while gardening. She now ambulates with difficulty using a walker, but she is determined to become independent again and to return to her own home. Her daughter, who is in the room with the patient, says, "I want to take Mother home with me because I'm concerned that she could fall and break her hip again. Mom says she doesn't really want to leave her own home, but she will do what is best." The daughter turns to her mother and says firmly, "Isn't that right, Mom?" The mother says, "Yes, I guess so," averting eye contact with both her daughter and you by looking down toward the floor.

3. Which of the following is the most appropriate response to the mother?
  - (A) "Are you sure you want to go home with your daughter?"
  - (B) "How would you feel if you fell again and had another fracture?"
  - (C) "Is this really your decision or is it your daughter's?"
  - (D) "I would like to talk with you in private now."
  - (E) "You are lucky to have a daughter who wants to take care of you."
  
4. Which of the following is most likely to prevent another fall and a possible fracture in this patient?
  - (A) Advise her to walk only when accompanied by an adult
  - (B) Ensure that she does not have orthostatic hypotension
  - (C) Provide her with assistance for activities of daily living
  - (D) Provide her with an electric wheelchair
  - (E) Request a visiting nurse to assess the safety of her living environment

**END OF SET**

---

5. A 27-year-old Mexican woman, gravida 4, para 2, aborta 1, who is at 25 weeks' gestation, comes to the emergency department because of painless vaginal bleeding that she noticed 2 hours ago after sexual intercourse with her husband. The patient has not received routine prenatal care during her pregnancy, though she was treated for chlamydia with azithromycin at 15 weeks' gestation. She gave birth to both of her daughters at home in Mexico via normal vaginal delivery. She had one spontaneous abortion at 5 weeks' gestation. Vital signs are temperature 37.0°C (98.6°F), pulse 100/min, respirations 24/min, and blood pressure 110/64 mm Hg. Sterile speculum examination shows 4 mL of blood in the vaginal vault. The cervix appears closed. Ultrasonography of the pelvis is most likely to show which of the following causes of bleeding in this patient?
  - (A) Cervicitis
  - (B) Placenta accreta
  - (C) Placenta previa
  - (D) Placental abruption
  - (E) Preterm labor
  
6. An 80-year-old African American woman is brought to the office for the first time by her son because she has signs of mildly decreasing mental function. She is having increasing trouble reading, writing, and watching television. She has mild, stable angina pectoris and she had an uncomplicated myocardial infarction 8 years ago. Physical examination discloses no abnormalities except for corrected visual acuity of 20/200 O.U., which appears to be caused by cataracts. Mini-Mental State examination score is 29/30. Which of the following is the most correct statement about this patient's condition?
  - (A) Her daily activities would likely improve if she had cataract extraction with lens implantation
  - (B) Her diminished mental status is a contraindication for a cataract operation
  - (C) Her history of cardiac disease and advanced age are contraindications for a cataract operation
  - (D) Her mental status should be reevaluated in 1 year
  - (E) You need more information to decide whether she would be helped by a cataract operation



7. A 70-year-old Vietnamese fisherman is brought to the emergency department by his son, who says that his father has had sweats occurring twice a night soaking his bedclothes, and a cough productive of yellow, foul-tasting fluid and blood-tinged sputum for the past 3 weeks. His appetite has been poor for 2 months and he has lost 12 kg (26 lb) during that time. Physical examination shows an emaciated man in acute distress; he is coughing frequently and deeply. Vital signs are temperature 37.8°C (100.0°F), pulse 98/min, and blood pressure 105/60 mm Hg. His respirations are shallow but not labored; loud rhonchi are heard on the right side of the chest. His liver and spleen are palpable and nontender. His inguinal nodes are matted but nontender. Chest x-ray is shown. Sputum smear discloses multiple neutrophils but normal flora. Appropriate diagnostic tests are completed to confirm the diagnosis. Which of the following is the most appropriate management at this time?
- (A) Antibiotic therapy
  - (B) Antifungal therapy
  - (C) Antimycobacterial therapy
  - (D) Referral for bronchoscopy
  - (E) Referral to a thoracic surgeon for right upper lobectomy
8. A 50-year-old man comes to the emergency department because of a 2-hour history of vomiting "coffee-ground" material. He has lost 4.5 kg (10 lb) in the past 6 months. Dark blood is obtained on passing a nasogastric tube. Which of the following is the most important factor in determining this patient's long-term prognosis?
- (A) Amount and rate of blood loss
  - (B) Cause of the bleeding
  - (C) History of previous gastrointestinal bleeding
  - (D) Initial hematocrit measurement
  - (E) Initial response to a bolus of saline

Items 9–10

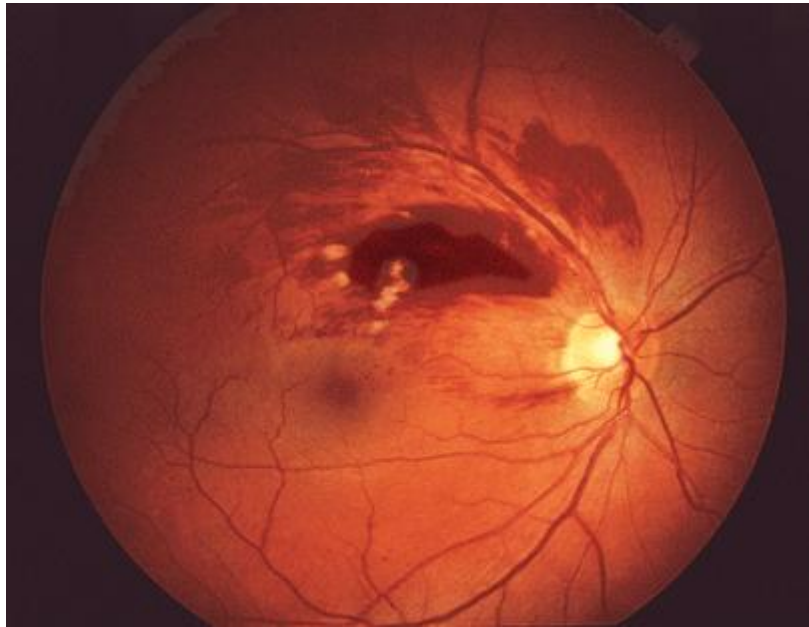A 22-year-old African American woman, gravida 1, para 1, is evaluated in the maternity ward of the hospital 24 hours after giving birth to a 4267-g (9-lb 7-oz) male infant via uncomplicated vaginal delivery. Following delivery, she underwent repair of a fourth-degree perineal laceration. She is currently able to walk to the bathroom and void without difficulty, but she has not had a bowel movement since delivery. Medical history is otherwise unremarkable and her only medications are prenatal vitamins. Vital signs are temperature 37.2°C (99.0°F), pulse 68/min, respirations 18/min, and blood pressure 128/86 mm Hg. The uterus is palpable to the level of the umbilicus. The vaginal laceration is not inflamed or swollen. Sutures are intact and there is no drainage from the site. Lochia is normal. Hemoglobin concentration is 10.8 g/dL. The patient states that she is concerned about her insurance company requirement that she stay in the hospital no longer than 48 hours post partum. She is worried that she will not be ready to leave tomorrow, as she is breast-feeding and needs more help from the nurses. She also is concerned about her bowel function and wants to stay until she is sure it will be normal. She asks if you would extend her stay to 72 hours post partum if she is not ready to leave tomorrow.

9. Which of the following is the most appropriate response to her request?
- (A) "I'm sure the insurance company will understand if you need another day, so you take whatever time you need before you go home."
  - (B) "Let me decide whether or not it is too soon for you to leave the hospital."
  - (C) "Let's see how you feel tomorrow and we can discuss the most appropriate time to leave then."
  - (D) "You concentrate on getting better and leave the insurance company to me."
  - (E) "Unfortunately I have no control over the insurance company, so you had better plan on leaving tomorrow."
10. Which of the following would be the most important indication for extending this patient's hospital stay beyond 48 hours post partum?
- (A) Abdominal distention and lack of appetite at 48 hours post partum
  - (B) Lack of bowel movement post partum
  - (C) Need for nursing assistance with breast-feeding
  - (D) Palpation of the uterus above the pubic symphysis for more than 48 hours post partum
  - (E) Persistence of lochia for more than 24 hours post partum

**END OF SET**

---

11. A 13-month-old child is brought to the emergency department because of urticaria, swelling of the lips, and difficulty breathing immediately after eating an egg. A potential risk for hypersensitivity reaction is posed by vaccination against which of the following illnesses?
- (A) Hepatitis
  - (B) Influenza
  - (C) Pertussis
  - (D) Poliomyelitis
  - (E) Typhoid fever
12. A 42-year-old white man is brought to the emergency department by his same sex partner because of confusion, diplopia, and mild weakness of his right arm. The patient is somewhat agitated and shows confusion for recent events. Temperature is 38.3°C (101.0°F). There is decreased pupillary response on the left with paresis of lateral gaze on the right. Peripheral leukocyte count is increased. Which of the following is the most appropriate next step in evaluation of this patient's neurologic signs and symptoms?
- (A) Bilateral carotid arteriography
  - (B) CT scan of the head
  - (C) EEG
  - (D) Lumbar puncture for examination of cerebrospinal fluid
  - (E) Serum HIV antibody test



13. A 35-year-old man is brought to the emergency department because of altered mental status. He is disoriented and complains about his vision. You have been his physician for the past 3 years. He has type 1 diabetes mellitus and a known history of intravenous drug abuse. You last saw him 2 weeks ago; at that visit his serum glucose concentration was 150 mg/dL 3 hours after eating. Today, vital signs are temperature 38.1°C (100.5°F), pulse 110/min, and blood pressure 190/70 mm Hg. On physical examination pupils are constricted; fundusoscopic examination of the left eye following dilation is shown. Which of the following is the most appropriate test at this time?
- (A) Blood cultures
  - (B) Chest x-ray
  - (C) Hemoglobin A<sub>1c</sub> level
  - (D) HIV antibody titer
  - (E) Plasma renin activity
14. A 38-year-old white letter carrier returns to the office for follow-up of abnormal results of a liver chemistry profile ordered 3 weeks ago during a routine examination. At that time, physical examination disclosed no abnormalities, but serum AST concentration was 72 U/L. Serum bilirubin and alkaline phosphatase concentrations were within the reference ranges. Medical history is significant for an episode of hepatitis A at age 22 years. He has no history of transfusions or intravenous drug use. He drinks two to three beers daily. Today's follow-up laboratory study results are shown:

Serum	
Anti-HAV	Positive
Anti-HBs	Negative
HBsAg	Positive
HBeAg	Positive

Which of the following is the most appropriate next step?

- (A) Begin interferon-alfa therapy
- (B) Begin corticosteroid therapy
- (C) Instruct him to cease alcohol consumption and retest him in 2 months
- (D) Order hepatitis B virus polymerase chain reaction test
- (E) Schedule liver biopsy

15. A 75-year-old white woman returns to the office after 6 months of missed appointments. She says she is feeling depressed. You have been treating her for years for a variety of disorders, including bipolar disorder, hypothyroidism, atrial fibrillation, peptic ulcer disease, and hypertension. She takes daily lithium carbonate, levothyroxine, haloperidol, sertraline, benztropine, digoxin, propranolol, ranitidine, and warfarin. She says, "I'm doing fine except for shakiness in my hands." She also says her mood is "a little depressed." She has no hallucinations or delusions. Vital signs are pulse 78/min with an irregularly irregular rhythm, and blood pressure 160/95 mm Hg. Physical examination shows a fine tremor of the hands when they are extended. On memory testing, she recalls one of three objects after 2 minutes. Which of the following is the most likely cause of the patient's depression?
- (A) Benztropine
  - (B) Digoxin
  - (C) Haloperidol
  - (D) Propranolol
  - (E) Ranitidine
16. A 68-year-old man is in the hospital because he requires mechanical ventilation for an exacerbation of chronic obstructive pulmonary disease. On the second day after admission he developed a pneumothorax on the right side that required tube thoracostomy. An air leak is noted for the next 24 hours, which now has stopped. However, the patient has become restless and combative. Breath sounds are diminished in the right side of the chest and the patient now has tachycardia. Blood pressure is 130/80 mm Hg. After ordering a STAT portable x-ray of the chest, which of the following is the most appropriate step?
- (A) Add 4 cm of positive end-expiratory pressure
  - (B) Administer  $\beta$ -blocking medications
  - (C) Administer alprazolam
  - (D) Remove the patient from the ventilator and ventilate him with a bag-valve mask
  - (E) Reposition the chest tube
17. A 36-year-old man comes to the office because of headaches that began 2 weeks ago. The headaches are moderately severe, are present when he awakens in the morning, and are relieved with over-the-counter analgesics. He has no prior history of headaches. He tells you he was promoted to an upper-level managerial position in his accounting firm about 8 months ago, which necessitated relocating. Physical examination now discloses no abnormalities except for blurring of the optic disc margins bilaterally. Which of the following is the most appropriate next step?
- (A) Begin a trial of a  $\beta$ -blocking medication
  - (B) Order CT scan of the head
  - (C) Order electroencephalography
  - (D) Refer him for consultation with a neurologist
  - (E) Refer him for consultation with a neurosurgeon
18. A 16-year-old high school student, whose prenatal course you have managed, gave birth to a 3256-g (7-lb 3-oz) baby girl during the night with the assistance of your associate. On morning rounds you note that the delivery records report that she had mildly elevated blood pressure during labor and sustained an estimated third-stage blood loss of 500 mL. Today blood pressure is 132/84 mm Hg, she is afebrile, and deep tendon reflexes are normal. The uterine fundus is firm and at the level of the umbilicus, and her perineum is slightly edematous. Hematocrit is 33%. She is cuddling her infant and normal bonding seems to be occurring. Which of the following is the most important next step in management?
- (A) Begin oral ferrous sulfate
  - (B) Begin oral methyl dopa
  - (C) Institute fundal massage
  - (D) Order daily sitz baths
  - (E) Provide education for well-baby care

Items 19–20

A 55-year-old man who has a long history of alcohol dependence comes to the office for his yearly follow-up visit. He has consumed 2 pints of vodka daily for many years and has a past history of blackout episodes during intoxication. Following a divorce from his second wife, he voluntarily "detoxified" himself, but this was complicated by "rum fits" with tactile and visual hallucinations. His medical history includes hypercholesterolemia controlled by diet, benign prostatic enlargement, and hypertension, for which he takes an  $\alpha$ -blocking medication. During the course of the examination, he tells you his twin brother recently died of colon cancer. It is clear from the conversation that he was very close to his brother and he feels that his only support system has left him. You discuss your concerns about his reliance on alcohol as a coping mechanism and ask if he would consider accepting help during this difficult time. He agrees.

19. Which of the following is the most appropriate next step?
- (A) Arrange for referral to a substance abuse treatment program while the patient is in the office
  - (B) Prescribe diazepam
  - (C) Prescribe disulfiram and discuss with him its use and potential withdrawal symptoms
  - (D) Refer him to Alcoholics Anonymous
  - (E) Suggest he attend an outpatient substance abuse treatment program in his area
20. Which of the following features in this patient's history is most closely associated with the risk for morbidity or mortality from alcohol withdrawal?
- (A) Absence of social support
  - (B) Blackout episodes during intoxication
  - (C) Family history of colon cancer
  - (D) Previous history of withdrawal seizures
  - (E) Use of an  $\alpha$ -blocking medication

**END OF SET**

---

21. A 29-year-old woman comes to the emergency department because she has had increasingly severe lower abdominal pain and nausea for the past 2 days. She is sexually active and does not use any contraception. Her last menstrual period ended 6 days ago. Temperature is 38.3°C (101.0°F). Physical examination discloses abdominal tenderness in the lower quadrants bilaterally with rebound and guarding. Pelvic examination discloses leukorrhea at the cervical os and tenderness of the uterus to palpation. The adnexal areas are tender but no masses are palpable. Which of the following is the most appropriate diagnostic study?
- (A) Cervical culture
  - (B) Culdocentesis
  - (C) Laparoscopy
  - (D) Serum  $\beta$ -hCG concentration
  - (E) Ultrasonography of the pelvis
22. A 28-year-old woman of Scandinavian descent comes to the office because of fatigue, generalized weakness, and palpitations. She is divorced and lives with her 4-year-old daughter. Medical history is significant for hyperthyroidism and mild ophthalmopathy caused by Graves disease. Before initiating therapy, the patient wants to know what she can expect in the future. In advising her about the prognosis, which of the following is the most accurate statement?
- (A) Graves ophthalmopathy will resolve as thyroid hormone secretion is lowered
  - (B) Malignant degeneration of the thyroid gland is a common complication
  - (C) She will not be able to become pregnant
  - (D) The thyroid will continue to increase in size with any nonsurgical treatment
  - (E) Untreated patients are at increased risk for cardiac arrhythmias

Items 23–24

A 38-year-old woman returns to the office for follow-up of tension headaches, which have not improved with trials of several appropriate medications. She has been married to a policeman for the past 6 years and has four children (ages 5 to 12 years). When asked if she has been under extra stress, she begins to cry. Bruises are evident on both arms. On further questioning, she says her husband hits her whenever he is drunk, which is at least 2 nights per week. She says, "He is nice...a good husband when he's sober. But when he drinks, oh he's awful! He accuses me of cheating on him. Last night he said he would kill me if I try to leave." Her husband is also your patient.

23. Which of the following is the most appropriate intervention?
- (A) Advise her to leave her home with her children and move in with her relatives
  - (B) Contact her husband's supervisor to discuss recent stress levels on the job
  - (C) Gather more information while remaining neutral, since both the husband and wife are your patients
  - (D) Refer her to a domestic violence program
  - (E) Seek a restraining order against her husband on her behalf
24. Which of the following is the most important question to ask at this time?
- (A) "Do you think this might be causing your headaches?"
  - (B) "Has your husband also lost his temper with any of the children?"
  - (C) "Have you been drinking at the time of the fights?"
  - (D) "Have you or your husband been receiving any kind of counseling?"
  - (E) "Why have you stayed in this marriage?"

**END OF SET**

---

25. A 4-year-old boy is brought to the office by his mother because he has become unmanageable at his day-care center. At previous visits he exhibited behavior problems to which his mother did not set limits. He constantly interrupted situations, seeking his mother's attention. She now reports that during the past few months his fighting, refusal to obey the day-care workers, and violations of "time out" have become much worse. He began day care at 6 weeks of age so that his mother could return to work. His father works as a house painter and has alcoholism. The boy has a 6-month-old sister who also attends the same day-care center. Records show his height and weight are at the 5th percentile, and his growth velocity is normal. There were no complications during the pregnancy with this child and he has not had any significant medical problems. Physical examination today discloses no abnormalities. Which of the following is the most likely cause for this child's worsening behavior?
- (A) Aggressiveness to compensate for a poor self-image caused by short stature
  - (B) Attention-deficit/hyperactivity disorder
  - (C) A reaction to his father's drinking
  - (D) Reduction in his mother's attention because of his new sibling
  - (E) A toxic reaction to organic fumes from his father's clothes and work materials
26. A 13-year-old girl is brought to the office for a health maintenance visit. She was diagnosed with Turner syndrome in infancy during a work-up for coarctation of the aorta. During today's visit, her mother reports that the girl has been talking about babies. You have been the patient's physician for the past 6 years and know she is prepubescent. You counsel the girl that if she wishes to have a family she will need to do which of the following?
- (A) Adopt
  - (B) Have amniocentesis if she gets pregnant
  - (C) Have an operation
  - (D) Receive genetic counseling
  - (E) Receive hormone treatment



27. You are asked to evaluate a 78-year-old German American woman who is admitted to the hospital for replacement of her left knee joint due to degenerative joint disease. She is a retired seamstress. She has type 2 diabetes mellitus, a long history of hypertension, and chronic renal failure presumed secondary to diabetes mellitus and hypertension. Reversible causes of renal failure have been excluded. She underwent a tonsillectomy at age 9 years and a laparoscopic cholecystectomy at age 68 years. Serum creatinine concentration on admission was 6.0 mg/dL. Her current therapy includes a low-sodium, low-protein American Diabetes Association (ADA) diet, enalapril, and acetaminophen. She and her husband live on a farm 90 miles from the nearest dialysis facility. In considering long-term treatment options for this patient, which of the following is the most appropriate factor to consider?
- (A) Her eligibility to receive Medicare
  - (B) Her history of an abdominal operation
  - (C) Her history of arthritis
  - (D) Her suitability for home dialysis
  - (E) Her willingness to move to the city

28. A 60-year-old man is admitted to the hospital for management of acute pancreatitis. Results of laboratory studies are shown:

Serum		Blood	
Amylase	1000 U/L	Hematocrit	42%
Calcium	8.4 mg/dL	WBC	14,000/mm <sup>3</sup>
Urea nitrogen	5 mg/dL		

Results of serum liver chemistry profile are within the reference ranges. After 48 hours of fluid therapy and observation, a poor prognosis would be indicated by which of the following laboratory studies?

- (A) Serum alanine aminotransferase (ALT) concentration of 106 U/L
  - (B) Serum amylase concentration of 2000 U/L
  - (C) Serum bilirubin concentration of 4.2 mg/dL
  - (D) Serum calcium concentration of 6.6 mg/dL
  - (E) Serum glucose concentration of 200 mg/dL
29. A 68-year-old white man comes to the office because of progressively worsening right groin pain for the past month. You last saw the patient 3 months ago for preoperative assessment for a total right hip replacement. For the past 5 years he has been treated with inhaled bronchodilators for emphysema resulting from an extensive history of smoking cigarettes. The patient is widowed and has lived alone in a mobile home since his wife died 4 years ago. Vital signs today are temperature 36.8°C (98.2°F), pulse 66/min, respirations 18/min, and blood pressure 110/82 mm Hg. Physical examination shows an unkempt man who appears much older than his stated age. He has evidence of alcohol on his breath; dentition is poor with several broken, loose teeth, and gingival pyorrhea is present. Lung sounds are distant and air entry is poor. Heart and abdomen are normal. There is no hernia present in the groin. With the exception of testicular atrophy, the patient's genitalia are normal. Which of the following is the most likely initial working diagnosis?
- (A) Iliac venous thrombosis
  - (B) Infected hip prosthesis
  - (C) Occult appendicitis
  - (D) Occult hernia
  - (E) Somatoform disorder

30. A 9-year-old boy is brought to the emergency department by his father because of lethargy. On physical examination, the boy is slightly lethargic and has deep respirations, which are 32/min. The father, who is a single parent, says, "He is always thirsty and he pees a lot." Results of laboratory studies are shown:

Serum	
Glucose	850 mg/dL
Na <sup>+</sup>	132 mEq/L
K <sup>+</sup>	4.1 mEq/L
Cl <sup>-</sup>	92 mEq/L
HCO <sub>3</sub> <sup>-</sup>	6 mEq/L

After admitting the boy to the hospital, which of the following is the most appropriate therapy?

- (A) Administer normal saline and add potassium once urinary output is adequate
  - (B) Correct the acidosis with oral bicarbonate solution
  - (C) Correct the dehydration with hypotonic saline solution
  - (D) Give phenobarbital to prevent hyponatremic seizures
  - (E) Institute intermediate-acting insulin to correct hyperglycemia
31. A 74-year-old white man with dementia is transferred to the emergency department from a nursing facility because of necrosis of the distal phalanx of the second toe on his right foot. He denies localizing pain. He has a history of hypertension, coronary artery disease, congestive heart failure, and mild renal insufficiency. Vital signs are temperature 37.0°C (98.6°F), pulse 92/min, respirations 16/min, and blood pressure 160/80 mm Hg. On physical examination he is thin and is in no distress. Chest has bilateral crackles at both lung bases. Cardiac and abdominal examination discloses no abnormalities. The extremities are thin and the distal phalanx of the second right toe is black. Mild erythema is present on the adjacent proximal skin but no purulence is noted. Bilateral carotid and femoral artery bruits are noted. Radial pulses are full. A pulsatile mass measuring approximately 2 cm is palpable in the right popliteal fossa. Dorsalis pedis and posterior tibial pulses are 3+ bilaterally. Which of the following is the most likely cause of this patient's gangrene?
- (A) Arterial embolus
  - (B) Hypercoagulable (thrombophilic) state
  - (C) Obliterative angiopathy
  - (D) Polyarteritis nodosa
  - (E) Raynaud syndrome
32. A 76-year-old German American man comes to the office because of early awakening at night. He has no difficulty falling asleep but routinely wakes up between 2:00 and 3:00 AM. The patient is a retired postal worker, and he has always been physically active. He has diabetes mellitus controlled by diet. He is not obese. The patient drinks one cup of coffee in the morning with breakfast and usually walks for exercise in the morning. Before retiring at night he has one alcoholic drink. He has no history of depression, nightmares, or snoring and he takes no over-the-counter medications. His wife of 45 years is also in good health. Vital signs are temperature 37.1°C (98.8°F), pulse 96/min and regular, respirations 18/min, and blood pressure 135/90 mm Hg. Physical examination shows a well-nourished, well-developed man. Examination of the head and neck is normal; there are no bruits or jugular venous distention. Chest is clear, heart is normal with S<sub>1</sub> and S<sub>2</sub>. Abdomen is soft and nontender with active bowel sounds and no organomegaly. Rectal examination is normal. Which of the following is the most appropriate management of this patient's insomnia?
- (A) Advise the patient to discontinue his bedtime drink of alcohol
  - (B) Advise the patient to read and snack in bed to relax
  - (C) Prescribe a vigorous pre-bedtime exercise regimen
  - (D) Prescribe sertraline
  - (E) Prescribe triazolam

Items 33–34

A 1-month-old white boy whom you saw at birth is brought to the office for a routine well-child visit. His birth history is unremarkable except for mild jaundice that subsided within a few days. His birth weight was 2718 g (6 lb; 10th percentile), and length was 50 cm (19.5 in; 30th percentile). His mother stopped breast-feeding when he was 6 days old. At today's visit, the infant is alert and active, and he cries until fed. He weighs 3.2 kg (7 lb; 5th percentile), and is 54.6 cm (21.5 in; 25th percentile) long. His mother tells you that, even when cuddled, the infant cries continually until fed. He always eats slowly, falling asleep before he finishes his formula. You find that formula flows adequately from the bottle nipple, and you detect no abnormalities on physical examination of the boy to explain his slow feeding. Urination and stooling patterns are normal. Serum urea nitrogen concentration is 10 mg/dL and serum thyroxine (T<sub>4</sub>) concentration is 10 µg/dL.

33. Which of the following is the most appropriate next step?
- (A) Advise his mother to resume breast-feeding
  - (B) Hospitalize the infant for parenteral hyperalimentation
  - (C) Prescribe hypercaloric formula (24 calories/oz)
  - (D) Prescribe liquid multivitamins
  - (E) Schedule him for placement of a feeding gastrostomy tube
34. At a follow-up visit 1 week later, which of the following factors would most likely indicate satisfactory progress in the treatment of the infant's problem?
- (A) The infant does not cry before feeding
  - (B) The infant finishes his formula at each feeding
  - (C) The infant no longer falls asleep while feeding
  - (D) The infant's weight increases by at least 0.2 kg (0.4 lb)
  - (E) Serum urea nitrogen concentration decreases to 6 mg/dL

**END OF SET**

35. A 62-year-old woman is brought to the emergency department because of obtundation. On physical examination, she has hypotension and tachycardia. Respirations are 24/min. She has cherry-red maculae on fundoscopic examination. Results of initial laboratory studies are shown:

Serum		Urine	
Urea nitrogen	37 mg/dL	Color	Clear
Na <sup>+</sup>	139 mEq/L	Specific gravity	1.010
K <sup>+</sup>	6.1 mEq/L	Glucose	Negative
Cl <sup>-</sup>	100 mEq/L	Proteins, total	2+
HCO <sub>3</sub> <sup>-</sup>	10 mEq/L	Ketones	Trace
Glucose	121 mg/dL	WBC	5–10/hpf
Osmolality	357 mOsmol/kg H <sub>2</sub> O	RBC	3–5/hpf
Arterial blood gas analysis on room air		Crystals	None
Po <sub>2</sub>	75 mm Hg	Casts	Rare epithelial cell casts
Pco <sub>2</sub>	26 mm Hg		
pH	7.09		
HCO <sub>3</sub> <sup>-</sup>	9 mEq/L		

Which of the following is the most likely explanation for these data?

- (A) Alcoholic ketoacidosis
- (B) Diabetic ketoacidosis
- (C) Isopropyl alcohol intoxication
- (D) Methanol intoxication
- (E) Salicylate intoxication

36. A 15-year-old African American girl comes to the emergency department because, she says, "something has been sticking out of my bottom since I had a bowel movement this morning." She has not had previous episodes, although for more than 1 year she has had occasional difficulty passing stools. She is not in pain but is afraid to move her bowels for fear that the problem will worsen. She tells you that she moved away from home more than a year ago and that her parents contribute nothing to her support. She has a 6-month-old child and lives with a 28-year-old female cousin. She has never been married and does not work or attend school. She has no other symptoms. In order to follow the correct procedure for treating a minor, which of the following is the most appropriate step prior to evaluating this patient's rectal problem?
- (A) Accept the girl's consent as sufficient
  - (B) Obtain a court order permitting evaluation
  - (C) Obtain the written consent of at least two licensed physicians
  - (D) Obtain written consent from at least one of her parents
  - (E) Obtain written consent from her 28-year-old cousin
37. A 35-year-old white man with spina bifida is admitted to the hospital for a urologic procedure. He has been functionally independent in activities of daily living and is employed doing inventory control in a local sporting goods store. He has maintained continence through periodic self-catheterization. The patient is paraplegic, has recurrent calcium oxalate kidney stones, and recent onset of incontinence secondary to detrusor and bladder neck dysfunction. Vital signs are normal. Physical examination shows a well-developed, well-nourished man in no acute distress. Aside from paraplegia, lower extremity muscle atrophy, and lower abdominal surgical scars, the physical examination discloses no abnormalities. He had an episode of anaphylaxis secondary to latex allergy during a previous operation for functional expansion of his bladder through a bowel anastomosis. Which of the following is most important to consider in the care of this patient?
- (A) Administration of injectable medications with disposable syringes
  - (B) Preparation of food by outside contractors
  - (C) Type of cleaning agents used to sterilize bed linens
  - (D) Use of rubber urethral catheters
  - (E) Use of topical moisturizing agents for skin care
38. A 14-year-old boy is brought to the walk-in clinic by his father late on a Saturday afternoon because his left ear is swollen and painful. The ear has been black and blue since he injured it in a wrestling match 3 days ago. Symptoms have increased significantly following a repeat injury during a match 3 hours ago. Vital signs are normal. The left ear is markedly swollen and tender to palpation. Which of the following is the most appropriate next step in management?
- (A) Reassure him and start aspirin therapy
  - (B) Reassure him and start codeine therapy
  - (C) Recommend that he apply cold packs to the ear for the next 12 hours
  - (D) Recommend that he apply hot packs to the ear for the next 12 hours
  - (E) Refer him to a surgeon for immediate drainage of the lesion
39. A 25-year-old woman who is 19 weeks pregnant comes to the office for a prenatal examination. Her father had classic hemophilia. A karyotype obtained from an amniotic fluid sample of the patient shows that the fetus is XY. Which of the following should you tell the patient regarding her infant?
- (A) The infant will neither have hemophilia nor be a carrier
  - (B) The infant has a 50% risk for hemophilia
  - (C) The infant has a 50% risk for being a carrier
  - (D) The infant has a 75% risk for hemophilia
  - (E) The infant has a 75% risk for being a carrier

40. An 18-month-old child is brought to the emergency department by his parents because of fever and irritability. The child was well until 4 days ago when he developed rhinorrhea, nasal congestion, and diarrhea. One week ago, he was seen in the office by your partner and received routine vaccinations at that time. His mother says he felt warm to touch 2 days ago, but his temperature was not taken. She has been giving him acetaminophen every 6 hours during the past 2 days. Since this morning, the child has been eating poorly. There is a 4-year-old sibling at home who is healthy. Vital signs are temperature 38.2°C (100.8°F), pulse 100/min, respirations 25/min, and blood pressure 100/70 mm Hg. On physical examination, the child is irritable. He is uncooperative during the examination, and his neck is stiff and painful when flexed. He is whining that he wants to go home. Extremities are cool, with normal capillary refill time, and there is no rash. These findings are most consistent with which of the following?
- (A) Acetaminophen toxicity
  - (B) Aseptic (viral) meningitis
  - (C) Gastroenteritis with mild dehydration
  - (D) Reye syndrome
  - (E) Vaccine reaction
41. A 22-year-old woman is brought to the emergency department by her parents because of muscular weakness, muscle twitches, and palpitations. She is extremely thin and somewhat cachectic. Her parents report that she has a history of self-induced vomiting and overuse of laxatives and thiazide diuretics. Routine blood studies are obtained. Which of the following findings is most likely to explain these signs and symptoms?
- (A) Decreased hematocrit and hemoglobin concentration
  - (B) Decreased serum glucose concentration
  - (C) Decreased serum potassium concentration
  - (D) Increased serum calcium concentration
  - (E) Increased serum sodium concentration
42. A 50-year-old woman comes to the office for the first time because of recurrent abdominal pain. Review of her extensive medical chart, which she has brought with her, discloses that she has a long history of varying physical complaints. Definitive causes for these complaints have not been found despite extensive diagnostic studies, consultations with many physicians, and several surgical explorations. She gives dramatic and exaggerated descriptions of her present and past symptoms, and she makes conflicting statements about her history. She has been hospitalized at least 23 times since age 18 years. Which of the following is the most likely diagnosis?
- (A) Borderline personality disorder
  - (B) Conversion disorder
  - (C) Histrionic personality disorder
  - (D) Occult medical disorder
  - (E) Somatization disorder
43. A 27-year-old woman comes to the office for her annual physical examination and says, "Two weeks ago I noticed some small bumps on the outside of my vagina. They don't hurt, but they do itch a little." She has never been pregnant and she takes an oral contraceptive. Physical examination shows several small, moist warts on the labia minora. VDRL test is negative. Pap smear shows moderate high-grade squamous intraepithelial lesions (HGSIL; CIN2). After removal of the vaginal warts, which of the following is the most appropriate next step?
- (A) Colposcopy
  - (B) Cone biopsy of the cervix
  - (C) Endometrial biopsy
  - (D) Hysterectomy
  - (E) Repeat Pap smear in 6 months

**NOTE: THIS IS THE END OF BLOCK 1.  
ANY REMAINING TIME MAY BE USED TO CHECK ITEMS IN THIS BLOCK.**

**Block 2**  
Items 44–86; Time - 57 minutes

**ALL ITEMS REQUIRE SELECTION OF ONE BEST CHOICE.**

44. A previously healthy 54-year-old man comes to the emergency department at his wife's insistence 6 days after a stray dog sprang up and bit his right leg while he and his wife were walking near the dog during a trip to South America. The bite punctured the skin. He immediately cleaned the wound thoroughly with soap and peroxide and has done so daily since the incident occurred. The area of the bite is not painful, and the patient has not had fever or chills. He takes no medications. He had a tetanus booster vaccination 3 years ago. Vital signs today are normal. Examination of the right lower extremity shows healing bite puncture wounds. There is minimal erythema and the area is not fluctuant. Lymph nodes in the groin are not palpable. Which of the following is the most appropriate next step?
- (A) Administer rabies vaccination
  - (B) Administer tetanus immune globulin
  - (C) Order cerebrospinal fluid analysis
  - (D) Order an MRI of the brain and spine
  - (E) No intervention is necessary at this time
45. A 35-year-old man with hypertension comes to the office because of high fever, malaise, and arthralgias during the past 4 to 5 days. He also mentions having painless red bumps on the palms of both hands during the past few days. His current medications are lisinopril and aspirin. He denies any alcohol or tobacco use but admits to the daily use of intravenous heroin during the past month. He has been careful to use clean needles except for one incident 2 weeks ago in which he shared needles with his girlfriend. His most recent heroin shot was yesterday. Vital signs today are temperature 39.8°C (103.6°F), pulse 120/min, respirations 20/min, and blood pressure 110/68 mm Hg. The patient appears weak and pale. Skin is warm and moist. Small, nontender lymph nodes are palpable in both axillae and in the anterior neck and supraclavicular regions. There is a new, grade 2/6 holosystolic murmur heard best below the xiphoid that radiates to the apex and is increased slightly during inspiration. There are several small, nontender, erythematous nodules on the palms of both hands. Physical examination is otherwise normal. Based on the physical findings, the most likely cause of his fever is infection with which of the following?
- (A) Hepatitis B
  - (B) HIV
  - (C) *Serratia marcescens*
  - (D) *Staphylococcus aureus*
  - (E) Treponema organisms
46. A 46-year-old married woman comes to the emergency department because of increased vaginal bleeding for 2 days. She says her menses have been irregular during the past 6 months and that she has not had a menstrual period for more than 2 months. She thinks she may be going through menopause. She says she has a history of leiomyomata uteri but has not had an operation or taken medication. Vital signs are normal. Abdominal examination is normal. Pelvic examination is consistent with an 8-week-sized uterus, which is slightly tender. A 5-cm right adnexal mass is palpated. The cervical os is closed, and there are small clots in the vaginal vault. Which of the following next steps is most appropriate?
- (A) Dilatation and curettage
  - (B) Endometrial biopsy
  - (C) Intravenous conjugated estrogen
  - (D) Pelvic ultrasonography
  - (E) Serum pregnancy test

Items 47–48

A 57-year-old man who manages his own accounting firm has a 5-year history of malignant melanoma that has been treated with local excision and immunotherapy. He now is admitted to the hospital for evaluation of constant pain in his back and left hip and an 11-kg (24-lb) weight loss. He and his wife of 35 years are worried that "the cancer may be back." Pelvic and abdominal CT scans show multiple bony metastases. He tells you, "I just want to die. I can't bear this."

47. Which of the following is the most appropriate initial intervention?
- (A) Adjust his analgesic regimen
  - (B) Arrange for him to be transferred to a psychiatric service
  - (C) Begin antidepressant medication
  - (D) Initiate hyperalimentation
  - (E) Refer him to a cancer patient support group
48. Which of the following symptoms would be most suggestive of a major depressive syndrome in this patient?
- (A) Anorexia
  - (B) Expressions of discouragement
  - (C) Insomnia
  - (D) Low energy
  - (E) Withdrawal from family

**END OF SET**

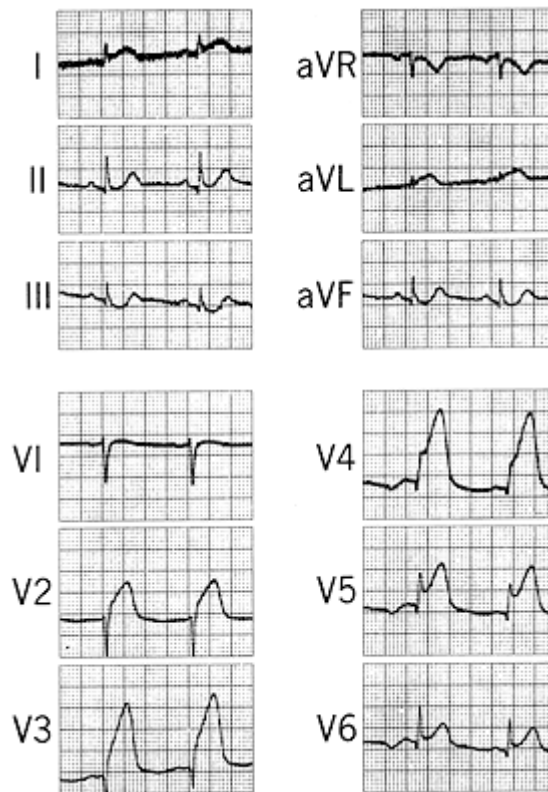
---

49. A 25-year-old woman has just had a second spontaneous abortion after 8 weeks of pregnancy. She has also had an elective abortion in the past. She has been told that her uterus is in a retroflexed position and this finding is confirmed on pelvic examination. The rest of the examination is normal. Which of the following is the most appropriate counseling?
- (A) Cervical incompetence is frequently associated with uterine malposition and is a likely contributor to spontaneous abortion
  - (B) Progesterone therapy is likely to decrease the risk for recurrent abortion and should be started as soon as pregnancy is diagnosed
  - (C) Renal abnormalities are frequently associated with uterine malposition, making it less likely that successful pregnancy can be expected
  - (D) Uterine malposition should be corrected by surgical suspension prior to further attempts at pregnancy
  - (E) The uterine position does not increase her risk for spontaneous abortion, and therefore no specific therapy is indicated
50. A 5-year-old boy is brought to the office by his mother because of recurrence of bed-wetting at night. He has a 3-month-old sister who is healthy. Physical examination discloses no abnormalities. Results of urinalysis are shown:

Specific gravity	1.010
Glucose	Negative
Protein	Negative
Microscopic	0–1 WBC/hpf, 0 RBC/hpf

Which of the following is the most important information to share with his parents?

- (A) The condition will cease if they reprimand him for deliberately wetting the bed
- (B) The condition is self-limiting, and they should take care to lessen the emotional impact on their child
- (C) The condition is a potentially serious problem and could represent chronic inflammation of the kidneys
- (D) The condition may be a precursor of diabetes mellitus
- (E) The condition signifies a serious underlying emotional disorder



51. A 38-year-old Hispanic bank executive comes to the emergency department because of the sudden onset of shortness of breath, light-headedness, diaphoresis, and weakness. He is afebrile. On auscultation of the lungs, bilateral basilar rales are heard. ECG is shown. Which of the following is the most likely diagnosis?
- (A) Acute pericarditis
  - (B) Hyperventilation syndrome
  - (C) Myocardial infarction
  - (D) Pulmonary embolism
  - (E) Spontaneous pneumothorax
52. A 3-year-old white girl is brought to the office by her parents for a follow-up visit 48 hours after receiving a 5-TU PPD skin test. The test was done as part of a routine screening for enrollment in a homeless shelter. Physical examination shows 10 mm of induration at the puncture site; the examination is otherwise normal. The parents tell you they are shocked by this finding since both of their skin tests were nonreactive. They say they were born in this country and tell you that their daughter has always been in good health. She has not had much medical care in the past 2 years but she has been healthy. Until moving into this shelter they had been "squatters" in vacant buildings. Which of the following is the most appropriate step at this time?
- (A) Call her previous physician to obtain more history
  - (B) Order a chest x-ray
  - (C) Order a test for HIV antibody
  - (D) Repeat the PPD skin test
  - (E) Schedule gastric aspiration for culture on successive days



Items 53–54

A 10-year-old girl, who has been undergoing treatment for chronic juvenile rheumatoid arthritis for the past 3 years, is brought to the office by her parents because of painful swelling of the right knee. She has had three episodes of painless swelling of her left knee and ankle, which have subsided spontaneously with rest and aspirin therapy. She has used no medications between episodes. Physical examination today discloses pronounced redness and warmth around the right knee, and a large effusion. Attempts at active and passive motion cause severe pain.

53. Which of the following is the most appropriate step at this time?
- (A) Joint aspiration
  - (B) Serum antinuclear antibody titer
  - (C) Serum rheumatoid factor assay
  - (D) Technetium 99m scan
  - (E) X-rays of the joint
54. Which of the following new symptoms or findings, if present, would most strongly indicate the need for further diagnostic studies?
- (A) Decreased viscosity of joint fluid
  - (B) Diffuse increase in technetium 99m uptake around the knee on bone scan
  - (C) Positive Gram stain of joint fluid
  - (D) Positive serum rheumatoid factor test
  - (E) Soft-tissue swelling seen on x-rays

**END OF SET**

---

55. A 31-year-old white woman comes to the office for initial prenatal care. She is 12 weeks pregnant by date of her last menstrual period. This is her fourth pregnancy; she has three healthy children. Her last delivery was by cesarean section because of fetal distress during labor. Her history includes heavy use of alcohol and cigarettes, and multiple sexual partners. In addition to routine prenatal laboratory work-up, the patient consents to an HIV antibody test. The tests are ordered. Later, the HIV test is reported as positive. At a follow-up visit the patient should be counseled regarding which of the following?
- (A) Amniocentesis is recommended to rule out congenital HIV infection
  - (B) Breast-feeding will increase the risk for transmitting HIV to the infant
  - (C) Immediate termination of pregnancy will decrease her risk for progression to AIDS
  - (D) Repeat cesarean delivery may increase the risk for vertical transmission of HIV
  - (E) The risk for perinatal HIV transmission is greater than 50%
56. While you are on rounds at a local nursing facility, the nurse mentions that your patient, a 79-year-old African American woman, appears to be a "poor eater." She was admitted to the nursing facility 3 months ago from the hospital where she was treated for congestive heart failure. Her daughter had moved away from the area, and nursing home placement was necessary because the patient could no longer function independently. Her present medications include furosemide and digoxin. Physical examination is normal except for a weight loss of 3.5 kg (7 lb) during the past 3 months. In your conversation with the patient, she says, "No, I'm not depressed, I just don't have an appetite anymore. Nothing tastes good to me. I have a little bit of nausea most of the time." Which of the following is the most appropriate initial diagnostic study?
- (A) Chest x-ray
  - (B) Complete blood count
  - (C) Determination of serum albumin concentration
  - (D) Determination of serum digoxin level
  - (E) Upper gastrointestinal barium study

Items 57–58

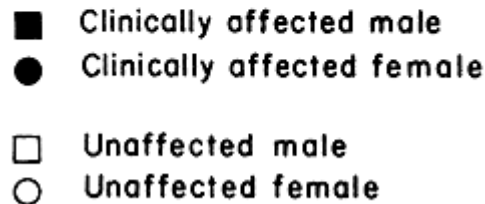
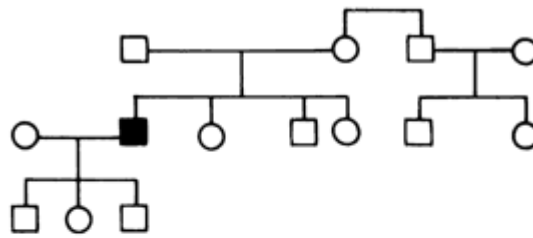
A 28-year-old white woman returns to the office for follow-up of hypertension. She says, "My blood pressure keeps getting worse, no matter what I do." Her hypertension had been controlled with a diuretic and a  $\beta$ -blocking medication for 4 years, but her blood pressure has steadily increased in the past 8 months despite taking maximum doses of the medications. She insists she takes her medications as directed. Family history is negative for hypertension. She does not smoke cigarettes. Height is 163 cm (5 ft 4 in) and weight is 75 kg (165 lb); BMI is 28 kg/m<sup>2</sup>. Vital signs today are pulse 96/min and blood pressure 165/110 mm Hg, standing, in both arms. Examination of the retina shows AV nicking. Abdominal examination discloses a new epigastric bruit. The remainder of the examination is normal.

57. Which of the following is the most appropriate diagnostic study to order next?
- (A) 24-Hour urine collection for creatinine clearance and protein excretion
  - (B) 24-Hour urine collection for vanillylmandelic acid, metanephrine and catecholamine excretion
  - (C) Serum and urine electrolyte concentrations
  - (D) Serum thyroid-stimulating hormone (TSH), cortisol, and aldosterone concentrations
  - (E) Urinalysis, and serum creatinine and urea nitrogen concentrations
58. Which of the following is the most appropriate imaging study?
- (A) Abdominal CT scan with contrast
  - (B) Abdominal ultrasonography
  - (C) Adrenal MRI
  - (D) Radionuclide thyroid scan
  - (E) Renal duplex ultrasonography

**END OF SET**

---

59. A 27-year-old nulligravid woman returns to the office to discuss results of a Pap smear obtained 2 weeks ago during a health maintenance examination. At that time, physical examination, including pelvic examination, disclosed no abnormalities. The patient's menstrual periods occur at regular 28-day intervals. She has been in a stable relationship with the same man for 3 years and she uses a diaphragm with spermicidal jelly for contraception. A Pap smear obtained 3 years ago showed no abnormalities. Pap smear obtained at her last visit shows evidence of marked inflammation suggestive of a high-grade squamous intraepithelial lesion. Which of the following is the most appropriate next step?
- (A) Advise the patient that her partner should use condoms for contraception and repeat the Pap smear in 3 months
  - (B) Do colposcopic examination of the cervix after application of 5% acetic acid solution
  - (C) Do conization of the cervix
  - (D) Reassure the patient and repeat the Pap smear in 3 months
  - (E) Treat the patient with metronidazole for 2 weeks and repeat the Pap smear in 3 months
60. A 46-year-old man with Marfan syndrome, aortic insufficiency, and mitral regurgitation comes to the emergency department because he has had severe substernal chest pain for the past 3 hours. He describes the pain as tearing in quality and radiating to the neck. One week earlier he experienced similar, but less severe chest pain and treated himself with aspirin. Which of the following is the most likely underlying cause for his worsening symptoms?
- (A) Acute bacterial endocarditis
  - (B) Acute myocardial infarction
  - (C) Dissection of the aorta
  - (D) Esophageal reflux with spasm
  - (E) Perforated peptic ulcer



**KEY**

61. A 30-year-old man who has been your patient for several years comes to the office for a periodic health evaluation. He has been healthy, but has a birth defect involving his hands and feet. He is missing the second and third metatarsals, metacarpals, and corresponding fingers and toes. He has three healthy children, and no one else in the family has this condition. He has adapted well to his condition. During your evaluation, he asks, "What do you think? If I have any more kids, will they have hands and feet like mine?" You review the family history and his pedigree, which is shown. His physical examination is otherwise normal. In addition to discussing your opinions with him, which of the following is the most appropriate next step?
- (A) Do a skin biopsy for fibroblast culture  
 (B) Order chromosome analysis of peripheral blood lymphocytes  
 (C) Order radionuclide scan of his hands and feet  
 (D) Order skeletal x-ray surveys of his three children  
 (E) Order no additional tests at this time
62. A 75-year-old woman comes to the office because she has band-like, burning pain in her right upper abdomen extending from the epigastrium around to the midline of the back. Physical examination discloses no abdominal tenderness to palpation. Findings on ultrasonography of the gallbladder are normal. Serum amylase concentration is within the reference range. Which of the following is the most likely diagnosis?
- (A) Acalculous cholecystitis  
 (B) Chronic relapsing pancreatitis  
 (C) Diverticulitis of the cecum  
 (D) Herpes zoster  
 (E) Penetrating duodenal ulcer
63. A 19-year-old woman comes to the emergency department because, she says, "I'm burning up." She is known to staff as an intravenous drug user. Physical examination discloses a systolic heart murmur over the precordium. An expected physical finding will be which of the following?
- (A) Decreased intensity of  $S_1$   
 (B) Increased intensity of the murmur with deep inspiration  
 (C) Increased intensity of the murmur with forced expiration  
 (D) Positive Kussmaul sign (rise in jugular venous pulse with inspiration)  
 (E) Right-sided gallop

64. A 26-year-old woman comes to the office because of fever, cough, and increasing shortness of breath for the past 3 days. She has been living in homeless shelters and says she uses intravenous drugs. She recently tested positive for HIV infection. She takes no medications and has no history of asthma, pneumonia, or tuberculosis. Her last medical evaluation was 5 years ago. Vital signs are temperature 39.0°C (102.2°F), pulse 100/min, respirations 28/min, and blood pressure 110/60 mm Hg. Auscultation of the chest discloses crackles and rhonchi posteriorly over the right lower lung field with tubular breath sounds and dullness to percussion. No sputum could be obtained due to splinting of the chest wall. Chest x-ray shows consolidation of the right lower lobe. Complete blood count and arterial blood gas analysis while breathing room air show:

Blood		Arterial blood gas analysis	
Hematocrit	36%	Po <sub>2</sub>	72 mm Hg
Hemoglobin	12.7 g/dL	Pco <sub>2</sub>	33 mm Hg
WBC	7800/mm <sup>3</sup>	pH	7.44
Neutrophils, segmented	70%		
Neutrophils, bands	16%		
Lymphocytes	14%		

Which of the following is the most likely diagnosis?

- (A) Legionnaires disease
  - (B) Pneumonia caused by *Pneumocystis jiroveci*
  - (C) Pneumonia caused by *Streptococcus pneumoniae*
  - (D) Pulmonary embolism
  - (E) Pulmonary tuberculosis
65. A 60-year-old man had a total thyroidectomy and excision of enlarged left jugular lymph nodes for follicular carcinoma. The operation was uncomplicated. He is receiving intravenous 5% dextrose and 0.45% saline with potassium. Twelve hours after the operation he develops circumoral numbness and paresthesias in his fingertips, and he becomes very anxious. Vital signs are temperature 37.6°C (99.7°F), pulse 90/min, respirations 16/min, and blood pressure 140/90 mm Hg. Physical examination discloses a dry neck dressing and no stridor. Extremities are warm, with brisk capillary refill time. Additional physical examination is most likely to show which of the following?
- (A) Babinski sign present bilaterally
  - (B) Chvostek sign
  - (C) Deviation of the tongue to the left side
  - (D) A drooping left shoulder
  - (E) Hyporeflexia
66. A 2-year-old African American child with sickle cell disease is brought to the emergency department by her parents because of painful swelling of her feet for the past 3 hours. Her temperature is 37.0°C (98.6°F). Physical examination shows swelling and tenderness of her feet; no other abnormal findings are noted. Results of laboratory studies are shown:

Hemoglobin	7.8 g/dL
WBC	13,000/mm <sup>3</sup>
Neutrophils, segmented	60%
Lymphocytes	40%

Which of the following is the most likely diagnosis?

- (A) Bone infarction
- (B) *Escherichia coli* sepsis
- (C) Pneumococcal sepsis
- (D) Osteomyelitis
- (E) Staphylococcal sepsis

Items 67–68

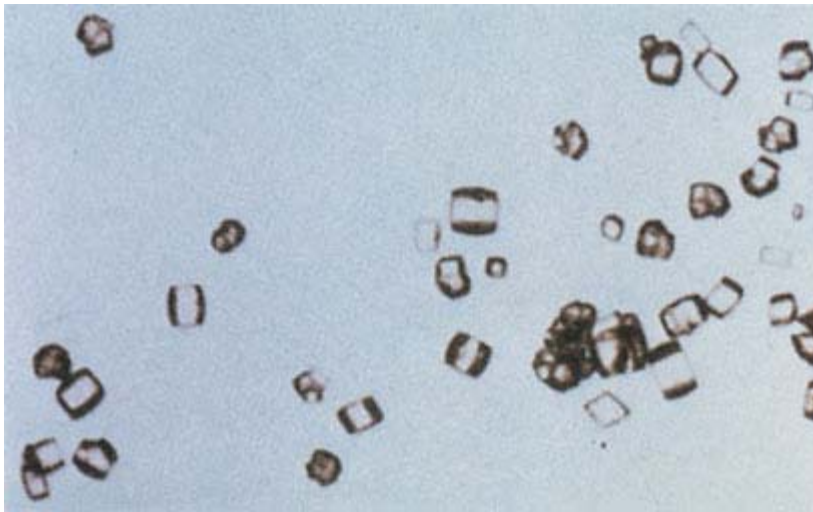
A 4-day-old female, Greek American newborn is brought to the office by her mother because the infant developed yellowing of her skin 1 day after hospital discharge and approximately 20 red spots over her skin yesterday. The infant has continued to feed well. Pregnancy and delivery were uncomplicated. Birth weight was 3400 g (7 lb 8 oz; 50th percentile). Apgar scores were 8 and 9 at 1 and 5 minutes, respectively. The mother, gravida 2, para 2, has blood group A, Rh-positive. The neonate's blood group is O, Rh-positive. Result of a direct antiglobulin (Coombs) test was negative. The neonate was breast-feeding and was doing well at the time of discharge. Weight today is 3250 g (7 lb 2 oz; 25th percentile). Physical examination discloses jaundice and scleral icterus. Many papules containing small vesicles with clear to slightly turbid fluid are present over the newborn's face, trunk, and extremities. No organomegaly or adenopathy is noted. Serum total bilirubin concentration is 8.7 mg/dL, and serum conjugated (direct) bilirubin concentration is 0.7 mg/dL.

67. In addition to scheduling a follow-up visit in 1 week, which of the following is the most appropriate next step regarding the newborn's jaundice?
- (A) Advise the mother to avoid eating foods containing large quantities of carotene
  - (B) Begin administering small doses of phenobarbital to the newborn
  - (C) Recommend discontinuation of breast-feeding until the jaundice has disappeared
  - (D) Recommend home phototherapy for the newborn
  - (E) Recommend no change in child care or feeding of the newborn
68. Which of the following is the most appropriate management for the newborn's rash?
- (A) 0.5% Hydrocortisone cream applied twice daily
  - (B) Daily wet-to-dry povidone-iodine (Betadine) soaks with gauze pads on each vesicle
  - (C) Polymyxin ointment applied twice daily
  - (D) Routine skin care with soap and water
  - (E) Scrubbing daily with entsofon cleanser firmly enough to unroof the vesicles

**END OF SET**

---

69. A 6-month-old male, Hispanic infant is brought to the office by his parents because of intermittent swelling of his right scrotum that is more pronounced when he cries. The swelling has never been red or "stuck." Vital signs are normal. A right inguinal hernia is confirmed on physical examination. In discussing repair of the hernia with the parents, you should inform them which of the following?
- (A) Herniorrhaphy can be postponed until age 2 years because many hernias close spontaneously
  - (B) Herniorrhaphy can be postponed until age 12 years because oligospermia does not develop before age 12
  - (C) Herniorrhaphy should be scheduled at the earliest convenient time
  - (D) Herniorrhaphy should be scheduled as an emergency operation
  - (E) There is no need to repair the hernia in childhood unless incarceration occurs
70. Three weeks ago a 45-year-old man was admitted to the hospital because of frostbite of both feet. He was treated by rapid rewarming and protective care of the feet. All the toes on the right foot have turned black. He has become slightly febrile and progressively more confused over the past few days. Examination discloses cellulitis in the midfoot. Which of the following is the most appropriate treatment?
- (A) Amputation
  - (B) Application of topical collagenase
  - (C) Debridement of necrotic skin over the toes
  - (D) Hyperbaric oxygen
  - (E) Whirlpool therapy

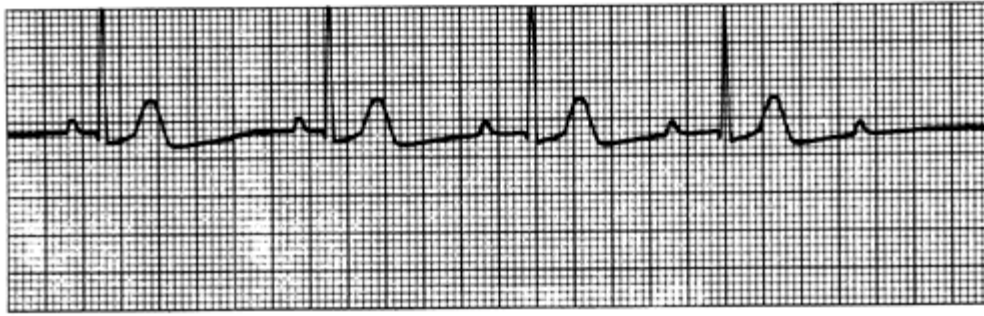


71. A 44-year-old African American construction worker comes to the emergency department because of excruciating left flank pain that radiates to his left testicle. He describes the pain as occurring in waves and says, "This is the worst pain I've had in my life, and that includes closing my thumb in my truck door." He is extremely restless and is in obvious pain. Genitalia are normal. Abdominal examination discloses intermittent guarding with spasms of pain. Plain x-ray of the abdomen shows no abnormalities. Results of urinalysis are shown:

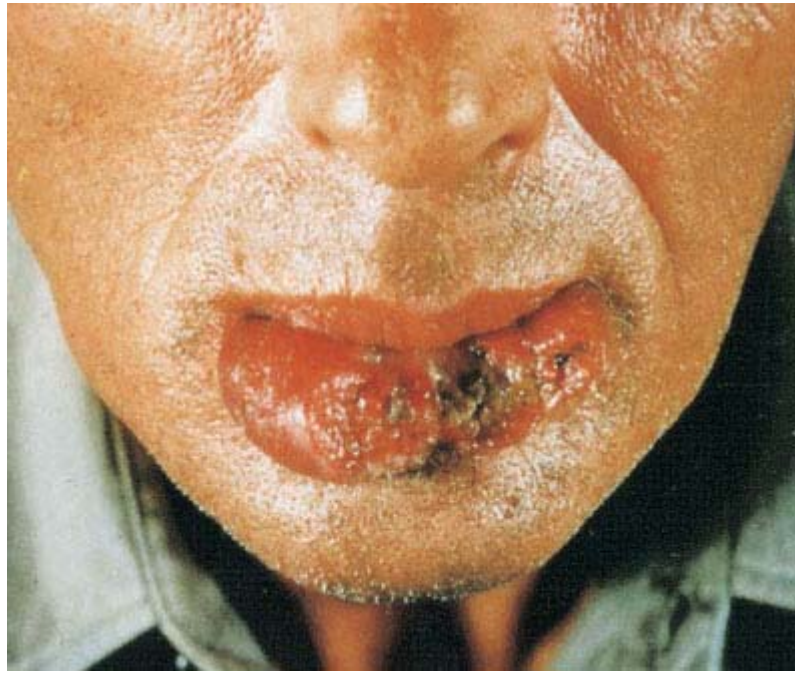pH	6.5
Specific gravity	1.025
Glucose	Negative
Protein	Negative

Urinary sediment is shown. Which of the following is the most appropriate diagnostic study?

- (A) CT scan of the abdomen
  - (B) CT scan of the kidney
  - (C) Culture of the urine
  - (D) Determination of serum uric acid concentration
  - (E) Measurement of 24-hour urinary calcium excretion
72. A 52-year-old woman who has had low back pain for several years is admitted to the hospital because the pain has suddenly worsened. Her current medications include oxycodone, amitriptyline, perphenazine, fluoxetine, and trazodone. The patient's body weight is 10% below ideal weight. Pupils are constricted and skin turgor is poor. She seems sluggish and her speech is slow. Neurologic examination and x-rays of the lumbosacral spine disclose no abnormalities. If a medication is responsible for this patient's mental condition, the medication is most likely to be which of the following?
- (A) Amitriptyline
  - (B) Fluoxetine
  - (C) Oxycodone
  - (D) Perphenazine
  - (E) Trazodone



73. A 65-year-old man is admitted to the hospital after he has an inferior wall myocardial infarction. Forty-eight hours later his vital signs are stable. ECG is shown. The most appropriate course of action is to do which of the following?
- (A) Administer atropine
  - (B) Administer isoproterenol
  - (C) Begin synchronized cardioversion
  - (D) Insert a pacemaker
  - (E) Observe
74. A healthy 2-year-old African American child is brought to the office for a routine well-child visit. The child was weaned at 6 months of age and began to walk at 10 months of age. On physical examination, she has mild bowlegs (10-degree genu varum). The parents should be advised about which of the following?
- (A) Braces should be applied immediately
  - (B) No treatment is needed at this time
  - (C) Surgical correction is necessary
  - (D) The child's intake of vitamin D should be increased
  - (E) A special exercise program is needed
75. A 3-year-old child is brought to the emergency department by his teenage sister because he refuses to walk. The sister reports that she has been babysitting for 3 days while her parents are away on a trip and that the boy has been fussy for the past 2 days. Physical examination is normal except for painful swelling of the left lower leg. In addition to radiography of the leg, you should obtain which of the following?
- (A) Abdominal ultrasonography
  - (B) CT scan of the abdomen
  - (C) CT scan of the head
  - (D) Skeletal survey
  - (E) Serum lead concentration
76. A 32-year-old man and his 29-year-old wife come to the office for evaluation for infertility. The wife's gynecologist has reported that her anatomic and physiologic evaluation disclosed no abnormalities and that assessment of potential male factors is needed. The husband is 188 cm (6 ft 3 in) tall with fair skin and little facial hair. He has mild gynecomastia and small, firm testicles. No sperm are seen on semen analysis. Which of the following tests is most likely to establish the underlying cause of this couple's infertility?
- (A) Karyotype from peripheral leukocytes
  - (B) Serum estrogen and testosterone concentrations
  - (C) Serum follicle-stimulating hormone and luteinizing hormone concentrations
  - (D) Serum prolactin concentration
  - (E) Testicular ultrasonography



77. A 58-year-old man comes to the office because of a lesion on his lower lip that developed 9 months ago. He has not seen a physician during the past 5 years and says, "My wife made me come to see you today." Physical examination of the lips discloses the findings shown in the photograph. The lower lip is fixed to the anterior aspect of the mandible. Which of the following is the most likely diagnosis?
- (A) Basal cell carcinoma
  - (B) Keratoacanthoma
  - (C) Leukoplakia
  - (D) Melanoma
  - (E) Squamous cell carcinoma
78. A 10-year-old boy is brought to the emergency department by his father because of left flank pain and tenderness. About 4 hours ago the boy was hit hard on the abdomen during a karate match. Abdominal CT scan shows a large splenic tear. In the pediatric intensive care unit his blood pressure is stabilized and his hematocrit is 45%. Which of the following is the most appropriate immediate step?
- (A) Continue pulse and blood pressure monitoring
  - (B) Do celiotomy and splenectomy
  - (C) Order diagnostic abdominal paracentesis
  - (D) Order intravenous urography
  - (E) Order radionuclide scan of the spleen
79. A 42-year-old woman with a history of multiple sclerosis comes to the office because she had a sudden loss of vision in the right eye. She has no history of diplopia. External ocular movements are normal but fundoscopic examination shows pallor of the optic disk. This patient's condition is most likely a result of demyelination of which of the following?
- (A) Medial longitudinal fasciculus
  - (B) Oculomotor nerve
  - (C) Optic nerve
  - (D) Trigeminal nerve
  - (E) Visual cortex



80. A 28-year-old woman who is known to be HIV-positive comes to the emergency department because of a 1-week history of increasing headaches, right-sided weakness, and disorientation. A generalized, tonic-clonic seizure occurs shortly after admission. Following the seizure, vital signs are normal. There is no nuchal rigidity. Funduscopic examination shows papilledema. There is also right hemiparesis and aphasia. Which of the following is the most likely diagnosis?
- (A) Meningioma
  - (B) Meningococcal meningitis
  - (C) Neurosyphilis
  - (D) Toxoplasmosis
  - (E) Tuberculous meningitis
81. A 5-year-old girl with a lumbar myelomeningocele is brought to the office by her mother for a periodic health evaluation. The girl has little motor function and no sensation below the waist. She has a neurogenic bladder requiring intermittent catheterization, and she also requires daily suppositories to aid in bowel movements. She does not have hydrocephalus but can walk only with the aid of braces and crutches. "I am pleased with how well she is doing," says the mother, "but I am so worried about what might happen to her later on." Which of the following is the most likely late complication in this patient?
- (A) Carcinoma of the bladder
  - (B) Chronic obstructive pulmonary disease
  - (C) Cor pulmonale
  - (D) End-stage renal disease
  - (E) Osteomyelitis of the femoral head
82. A 26-year-old man is brought to the emergency department by his family because he has been telling them that he is being followed by gangsters and that they are going to kill him. The family states that he has a history of drug abuse. Temperature is 37.8°C (100.0°F), pulse is 110/min, and blood pressure is 160/95 mm Hg. His pupils are dilated. The remainder of the physical examination discloses no abnormalities. Which of the following drugs most likely caused this reaction?
- (A) Alcohol
  - (B) Cocaine
  - (C) Diazepam
  - (D) Heroin
  - (E) Methaqualone
83. Several patients with hypertension whom you have treated for many years have recently had strokes. You are frustrated by this outcome and review the literature on the efficacy of antihypertensive treatments in preventing stroke. A large, multicenter, randomized trial shows that a particular antihypertensive medication lowers the 5-year risk for stroke from 8 per 1000 patients to 6 per 1000 patients, providing a relative risk reduction of 25%. Based on this study, the number of patients with hypertension who must be treated to prevent one stroke is which of the following?
- (A) 4
  - (B) 75
  - (C) 250
  - (D) 500
  - (E) 2000

Items 84–85

A 48-year-old Native American construction worker, who sustained a comminuted fracture of his left tibia and fibula 4 months ago, is transferred from the rehabilitation facility to the emergency department because of a 3-hour history of dyspnea and chest pain. During the past 3 months since sustaining the fracture, he has resided in the rehabilitation facility with his left lower extremity fully immobilized. He now describes an aching discomfort over the right superior anterior chest and the right scapula posteriorly. Family history is strongly positive for heart disease.

84. In questioning the patient further, an important point in the history would be the relationship of the pain to which of the following?
- (A) Change of position
  - (B) Deep breathing
  - (C) Eating
  - (D) Swallowing
  - (E) Walking
85. The presence of a right pleural friction rub in this patient would suggest which of the following?
- (A) Pericarditis
  - (B) Pneumonia
  - (C) Pneumothorax
  - (D) Pulmonary embolus with infarction
  - (E) Pulmonary embolus without infarction

**END OF SET**

---

86. A 68-year-old woman, who underwent flexible sigmoidoscopy 6 hours ago in the office as part of routine screening, returns to the office because of left lower quadrant abdominal pain, fever, nausea, and vomiting. During the procedure, a 3-cm polyp was found in the sigmoid colon and was removed. Vital signs now are temperature 38.1°C (100.6°F), pulse 110/min, respirations 26/min, and blood pressure 120/60 mm Hg. Abdominal examination discloses bowel sounds, and tenderness and guarding in the left lower quadrant. Rectal examination shows no stool and tenderness only superiorly. Which of the following is the most appropriate next step?
- (A) Obtain angiography to rule out intestinal ischemia
  - (B) Obtain immediate consultation with a surgeon
  - (C) Pass a soft rubber rectal tube under fluoroscopy
  - (D) Repeat the flexible sigmoidoscopy to evaluate the operative site
  - (E) Start hydrocortisone, intravenously, to decrease any inflammatory response

**NOTE: THIS IS THE END OF BLOCK 2.  
ANY REMAINING TIME MAY BE USED TO CHECK ITEMS IN THIS BLOCK.**

*Answer sheet for SPEX Sample Questions*

**Block 1 (1-43)**

1. \_\_\_\_
2. \_\_\_\_
3. \_\_\_\_
4. \_\_\_\_
5. \_\_\_\_
6. \_\_\_\_
7. \_\_\_\_
8. \_\_\_\_
9. \_\_\_\_
10. \_\_\_\_
11. \_\_\_\_
12. \_\_\_\_
13. \_\_\_\_
14. \_\_\_\_
15. \_\_\_\_
16. \_\_\_\_
17. \_\_\_\_
18. \_\_\_\_
19. \_\_\_\_
20. \_\_\_\_
21. \_\_\_\_
22. \_\_\_\_

23. \_\_\_\_
24. \_\_\_\_
25. \_\_\_\_
26. \_\_\_\_
27. \_\_\_\_
28. \_\_\_\_
29. \_\_\_\_
30. \_\_\_\_
31. \_\_\_\_
32. \_\_\_\_
33. \_\_\_\_
34. \_\_\_\_
35. \_\_\_\_
36. \_\_\_\_
37. \_\_\_\_
38. \_\_\_\_
39. \_\_\_\_
40. \_\_\_\_
41. \_\_\_\_
42. \_\_\_\_
43. \_\_\_\_

*Answer sheet for SPEX Sample Questions*

**Block 2 (44-86)**

- 44. \_\_\_\_
- 45. \_\_\_\_
- 46. \_\_\_\_
- 47. \_\_\_\_
- 48. \_\_\_\_
- 49. \_\_\_\_
- 50. \_\_\_\_
- 51. \_\_\_\_
- 52. \_\_\_\_
- 53. \_\_\_\_
- 54. \_\_\_\_
- 55. \_\_\_\_
- 56. \_\_\_\_
- 57. \_\_\_\_
- 58. \_\_\_\_
- 59. \_\_\_\_
- 60. \_\_\_\_
- 61. \_\_\_\_
- 62. \_\_\_\_
- 63. \_\_\_\_
- 64. \_\_\_\_
- 65. \_\_\_\_

- 66. \_\_\_\_
- 67. \_\_\_\_
- 68. \_\_\_\_
- 69. \_\_\_\_
- 70. \_\_\_\_
- 71. \_\_\_\_
- 72. \_\_\_\_
- 73. \_\_\_\_
- 74. \_\_\_\_
- 75. \_\_\_\_
- 76. \_\_\_\_
- 77. \_\_\_\_
- 78. \_\_\_\_
- 79. \_\_\_\_
- 80. \_\_\_\_
- 81. \_\_\_\_
- 82. \_\_\_\_
- 83. \_\_\_\_
- 84. \_\_\_\_
- 85. \_\_\_\_
- 86. \_\_\_\_

*Answer key for SPEX Sample Questions*

***Block 1***

1. A	10. A	19. A	28. D	37. D
2. D	11. B	20. D	29. B	38. E
3. D	12. B	21. A	30. A	39. B
4. E	13. A	22. E	31. A	40. B
5. C	14. C	23. D	32. A	41. C
6. A	15. D	24. B	33. C	42. E
7. C	16. E	25. D	34. D	43. A
8. B	17. B	26. A	35. D	
9. C	18. E	27. D	36. A	

---

***Block 2***

44. A	53. A	62. D	71. A	80. D
45. D	54. C	63. B	72. C	81. D
46. E	55. B	64. C	73. E	82. B
47. A	56. D	65. B	74. B	83. D
48. E	57. E	66. A	75. D	84. B
49. E	58. E	67. E	76. A	85. D
50. B	59. B	68. D	77. E	86. B
51. C	60. C	69. C	78. A	
52. B	61. E	70. A	79. C	